PUBLIKATIONEN

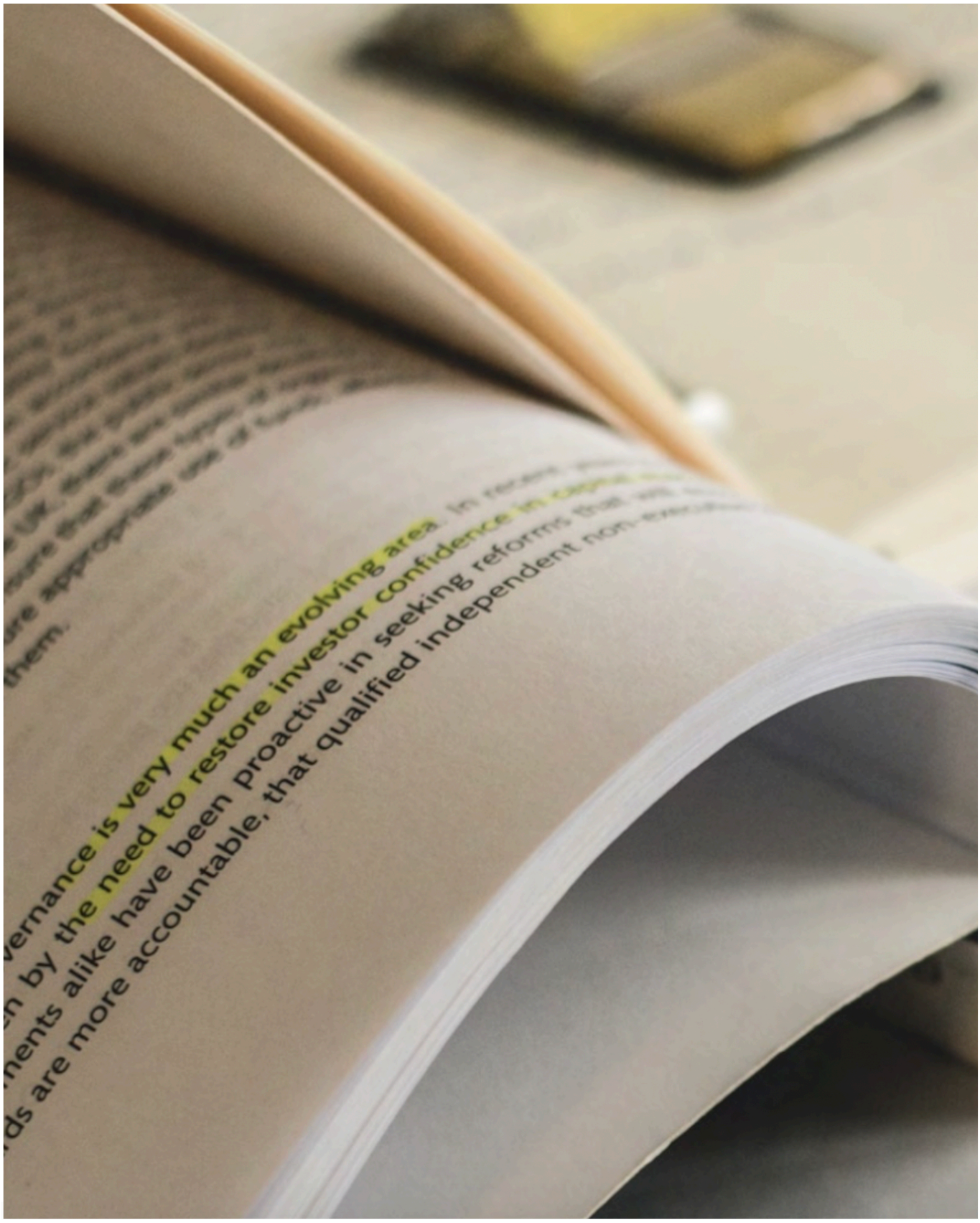

The Breast 20 (2011) 21–25

Contents lists available at ScienceDirect

The Breast

journal homepage: www.elsevier.com/brst

Original article

Factors affecting post-operative complications following skin sparing mastectomy with immediate breast reconstruction

Kerry Davies*, Lyra Allan, Paul Roblin, David Ross, Jian Farhadi

GKT Cancer Reconstructive Service, St.Thomas' Hospital, Westminster Bridge Road, London SE1 7EH, UK

ARTICLE INFO

Article history:
Received 18 January 2010
Received in revised form
14 April 2010
Accepted 15 June 2010

Keywords:
Breast reconstruction
Post-operative complications
Incision pattern
Body mass index
Breast weight

ABSTRACT

Skin sparing mastectomy (SSM) followed by immediate breast reconstruction (IBR) is not only oncologically safe but provides also significant benefits both cosmetically and functionally. The superiority of this technique can only be fully established, however, by developing a framework for minimising complications. The present study seeks to elucidate the key factors affecting outcome.

Methods: Data for all skin sparing mastectomies with immediate autologous and implant based reconstructions, performed in a three year period (2006–2008) was retrospectively collated. Complications were classified into major and minor. Patients were excluded who had flap loss due to vascular complications.

Results: The total number analysed was 151. 17.2% had major complications, 23% had minor and 61% had no complications. The Wise and the "tennis" incision had significantly higher rates of wound dehiscence when compared with the periareolar incision ($p = 0.025$, $p = 0.098$). There was no significant difference between diathermy or blade dissection techniques, or the use of subcutaneous adrenaline infiltration. Increasing BMI was associated with increased skin flap necrosis and wound dehiscence, and an excised breast mass of greater than 750 g and a sternal notch to nipple length of greater than 26 cm are associated as well with increased flap-related complications ($p = 0.0002$, $p = 0.0049$).

Conclusion: Factors such as Wise pattern and tennis racquet incision, BMI and breast mass and sternal notch to nipple length adversely affect skin sparing mastectomy flap morbidity. These factors should be factored in to patient selection and operative planning especially for obese and large breasted women undergoing skin sparing mastectomy with immediate breast reconstruction.

© 2010 Elsevier Ltd. All rights reserved.

Introduction

Skin sparing mastectomy (SSM) was first described in 1962 as a technique for preserving the skin envelope to retain the shape of the breast.[1]These early SSMs were used solely for the purpose of removal of benign breast conditions. By the early 90s SSM came to be used in conjunction with malignant tumours. Toth & Lappert (1991)[2] described the SSM technique in association with the removal of malignant tumours with the nipple areola complex (NAC) and the biopsy site which allowed access to the axilla for possible dissection. This was found to greatly enhance the aesthetics of the breast.[2,3] It provides excellent symmetry without the need to manipulate the opposite breast.[4]

SSM preserves the infra-mammary fold and breast envelope[5] which is a major factor affecting the reconstructed breast. Over time the neoparenchyma moulds to assume the shape of the original breast envelope allowing symmetry and ptosis to be achieved.[5] SSM prevents transverse scars associated with free flaps. By de-epithelialising the flap, the free flap is only visible as an island for the NAC, preventing contrast between the pale abdominal skin and the breast tissue[4,7] providing an ideal colour and texture to the breast skin.[8] In addition, the sensation of the skin of the breast will largely be retained.[9]

Local recurrence rates are similar for SSM and non-SSM for immediate breast reconstructions.[10–12] Local recurrence is associated with the biology of the tumour and the stage of the disease. It is not affected by the use of immediate or SSM.[13] In a review of current practice in the UK, Sotheran and Rainsbury (2004)[5] found that the most common incisions were periareolar (56%), elliptical (22%), reduction pattern (12%) and tennis racquet (10%). Complications following SSM include skin necrosis, infection, wound dehiscence, haematoma and seroma with most SSM associated complications occurring in the initial post-operative period.[8] It is essential to reduce complications as delays in adjuvant chemotherapy and radiotherapy may result.[9] Skin necrosis or infection may lead to oedema, fibrosis and wound contraction. This usually

* Corresponding author.
E-mail address: kerry.angeletti@gmail.com (K. Davies).

0960-9776/$ – see front matter © 2010 Elsevier Ltd. All rights reserved.
doi:10.1016/j.breast.2010.06.006

results in a distorted breast shape, retraction of the skin envelope, less ptosis and asymmetry.[6] The patient may have to undergo a prolonged course of redressings, possible secondary procedures, which results in an impaired overall aesthetic result.[14]

The purpose of this study was to identify the factors affecting flap morbidity and to provide an outcome analysis to enhance selection criteria and operative planning for patients undergoing skin sparing mastectomy with immediate breast reconstruction. Variables were categorised into surgical factors; SSM pattern, reconstruction type, diathermy versus knife technique, subcutaneous adrenaline infusion and patient related factors; breast volume, body mass index, and sternal notch to nipple length.

Patient and methods

Data for all skin sparing mastectomies with immediate autologous reconstruction; Superior gluteal artery perforator flap (S-GAP), deep inferior epigastric perforator flap (DIEP), muscle sparing transverse rectus abdonimis myocutaneous flap (MS-TRAM), superficial inferior epigastric artery flap (SIEA), transverse myocutaneous gracilis (TMG), and latissimus dorsi (LD) flap reconstruction with implant performed at St. Thomas' Hospital from Jan 2006–April 2008 was retrospectively collated. Five consultant breast surgeons and four consultant plastic surgeons performed the surgeries using our standardised post-operative protocol consisting of the use of antibiotics for three days, an overnight recovery stay with invasive monitoring plus a bear hugger warming blanket. No vasoactive drugs were used. Patients were offered two choices of either implant based or autologous breast reconstruction. All patients undergoing autologous breast reconstruction were included in the study. Those having implant based reconstruction were excluded as it was hypothesised that autologous flaps provide a vascular bed for a skin sparing mastectomy flap, hence implant only reconstructions could potentially skew results.

Complications, which occurred in the immediate post-operative period 0–10 days, were classified into major and minor. Major complications included haematoma requiring surgery and skin flap necrosis requiring surgical debridement and cover by split skin graft. Minor complications included haematoma, infection, seroma and wound dehiscence not requiring surgery or drainage. Patients were excluded who had flap loss due to vascular complications, were smokers or were diabetic as these factors have been shown to adversely affect post-operative outcomes. Statistical analysis was performed using a two-tailed Fisher's Exact Test. This is a non-parametric test of statistical significance for bivariate tabular analysis, which measures the deviation of the sample from expectation. A p value of less than 0.05 was considered statistically significant.

Results

The total number mastectomies analysed was 151, S-GAP 14%, DIEP 31%, TRAM 36% and LD flaps 19%. 17.2% had major complications, 23% had minor and 61% had no complications. Data was collected for 146 mastectomy incision patterns including periareolar (round), wise, tennis racquet and elliptical. The elliptical were excluded from statistical analysis due to the small number. See Graph 1.

Of the minor complications, wound dehiscence was significantly higher in the wise pattern group (see Graph 2) additionally there was an association in the tennis pattern group $p = 0.0977$. There were also significantly less patients having no complications in the wise pattern group $p = 0.046$ (Table 1).

Complications associated with surgical incision types were categorised into those who had dissection using diathermy technique, and those who had dissection with a surgical blade. There were no significant correlations between any of the variables, $p = 0.78$ for major complications and $p = 0.33$ for minor complications. Similar results were found for those who had subcutaneous infiltration of adrenaline solution, $p = 0.23$ for major complications and $p = 0.64$ for minor complications. The breast reconstruction procedure was found to have an effect on post-operative complications. See Graph 3. S-GAP has significantly less major complications $p = 0.0001$. The TRAM flap had significantly more minor complications $p = 0.002$ and the DIEP reconstruction was associated with significantly more complications both major, $p = 0.05$ and minor $p = 0.0023$.

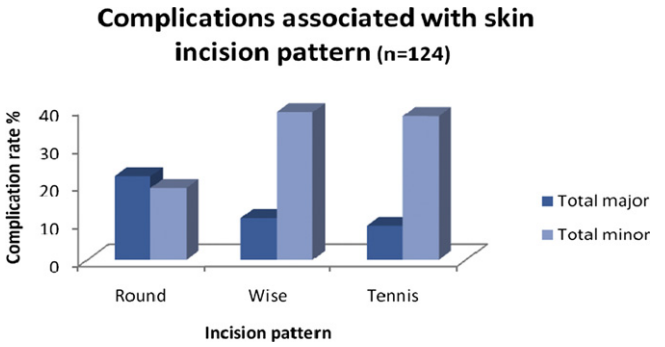

Graph 1. Complications associated with incision pattern ($n = 142$) and listings of how complications were categorised into major and minor.

Graph 4(a) and (b) demonstrate there was a significant correlation between BMI and flap necrosis and wound dehiscence. The higher the BMI, the stronger the correlation. See Table 2. Patients with a BMI <26 kg/m^2 are less likely to have any complications when compared with BMI >26 kg/m^2 $p = 0.0001$.

Complications associated with excised breast mass were significantly higher in women with an excised mass greater than 750 g $p = 0.0002$. This difference was largely due to the increased incidence in wound dehiscence with breast mass greater than 750 g, $p = 0.0099$, see Graph 5. Patients with an SN-N distance of greater or equal to 26 cm were more likely to have post-operative complications, $p = 0.0049$, however this was not specific to major, $p = 0.134$ or minor, $p = 0.104$ complications.

Discussion

The complexity of microvascular procedures involved in free flaps has lead to inherent risks of complications which include total flap loss, partial flap loss, fat necrosis and abdominal bulge or hernia.[15] Perfusion of the fasciocutaneous component of the grafted flap may be compromised. As the collateral vessels and perforators

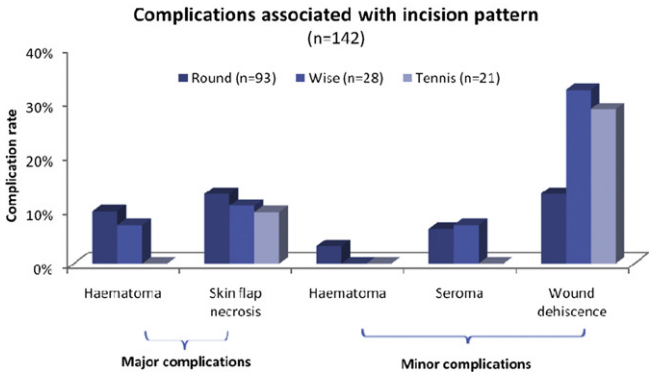

Graph 2. Complication rates associated with skin incision pattern highlighting major and minor complications.

Table 1
Complications associated with skin incision pattern ($n = 142$).

Complications	Round $n = 93$	Wise $n = 28$	p	Tennis $n = 21$	p
None	61	12	0.046	12	0.46
Haematoma (surgical)	9	2	1	0	0.207
Flap necrosis	12	3	1	2	0.66
Haematoma (conservative)	3	0	1	0	1
Infection	0	0	1	2	0.0326
Seroma	6	2	0.43	0	0.228
Wound dehiscence	12	9	0.025	6	0.0977

are ligated, there is an alteration in perfusion that may result in venous congestion or arterial insufficiency. With time the flow characteristics improve and the arterioles and venules dilate and neovascularisation occurs. However, when perfusion remains deficient, flap morbidities such as total, partial flap necrosis, venous congestion and fat necrosis may occur[15].

Kroll (2000)[16] reduced the incidence of fat necrosis from 62% to 17.4% by selecting a vein of at least 1 mm in diameter, a palpable pulse on the artery and a flap volume that was less than 70% of the total flap. Basing the flap on two perforators increases security in case of accidental vessel damage during the dissection. Including more than two perforators may decrease flap mobility and interfere with positioning on the thorax.[17] Women with breast volume >1000 cc may be at increased risk for flap-related morbidity due to inadequate vascular perfusion and may be better candidates for the TRAM flap.[15] Literature shows rates of partial flap loss ranging from 0 to 9% for DIEP and 0–38% for TRAM and total flap loss of 0–5% for DIEP and 0–3.5% for TRAM.

The periareolar incision technique was found to have significantly lower rates of complications compared with Wise and tennis incisions. Patients with small areola (<3 cm) may not be good candidates especially if the breast tissue is large. In women with large breasts, the periareolar approach may lead to increased breast skin tension, flap irregularities and inadequate resection.[8] In these cases a racquet incision may be used to facilitate better access to the borders of the breast and the axilla.[18] Meretoja et al. (2008)[9] found the tennis racquet incision had a five times greater incidence of wound edge necrosis compared with periareolar incision, however, the sample size was small ($n = 60$ with 15 having complications). In our study the incidence of wound edge necrosis was twice as high

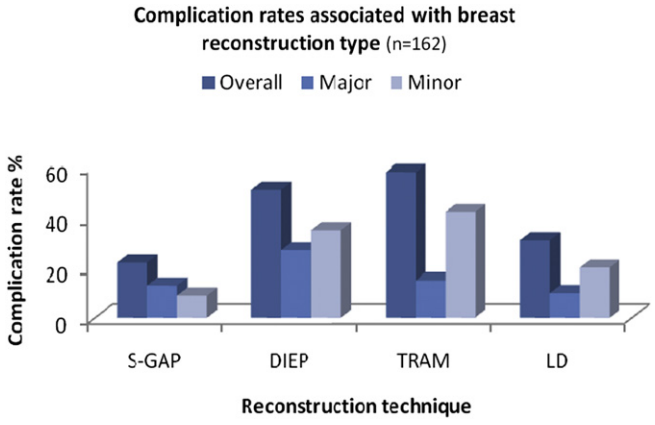

Graph 3. Complication rates associated with breast reconstruction type. S-GAP = Superior gluteal artery perforator flap, DIEP = Deep inferior epigastric perforator flap, TRAM = muscle sparing transverse rectus abdonimis myocutaneous flap and LD = latissimus dorsi flap.

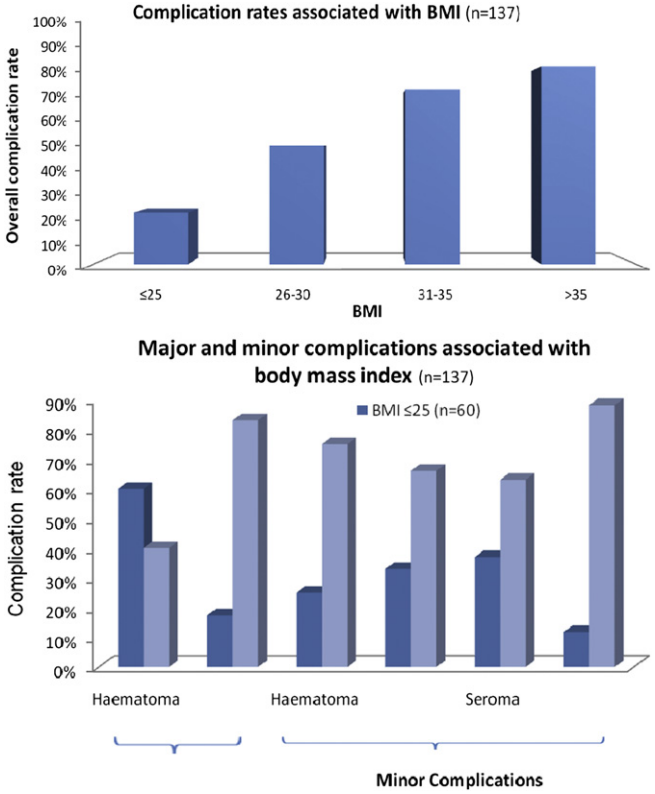

Graph 4. (a) highlighting the overall percentage complication rates for all skin flap types in association with body mass index. (b) Complication rates associated with a body mass index of greater than or less than 25, highlighting the major and minor complication type. BMI = Body Mass Index.

in the tennis racquet incision group (28.6% versus 12.9% for the round) but there were some differences in the classification criteria for complications. For example Meretoja et al. (2008)[9] included transient epidermolysis in their mild complications. Necrosis was noted mainly at the junction of the periareolar component and the lateral extension. This was considered to be due to damage to the microvasculature at the acute edges of the skin flaps.

A reduction pattern SSM is typically performed using a Wise pattern incision.[18] The Wise pattern was originally described for breast reduction procedures. It offers the surgeon wide exposure for performing the mastectomy, it limits scarring of the upper pole of the breasts and allows control of the skin envelope in both the vertical and horizontal axes.[19] Large breasts have a high incidence of flap necrosis and partial flap loss.[20] The Wise pattern SSM is indicated in large and ptotic breasts, suprasternal to nipple distance >21 cm[20] and in patients requiring contra lateral breast reduction

Table 2
Complications associated with BMI ($n = 138$).

Complications	<26 $n = 61$	26–30 $n = 52$	p	31 + $n = 25$	p
None	48	25	0.0008	6	0.0001
Haematoma (surgical)	6	3	0.5030	2	1
Flap necrosis	2	8	0.0420	7	0.0021
Haematoma (conservative)	1	1	1	2	0.2013
Infection	0	2	0.2095	0	1
Seroma	4	3	1	2	1
Wound dehiscence	4	12	0.0151	10	0.0004

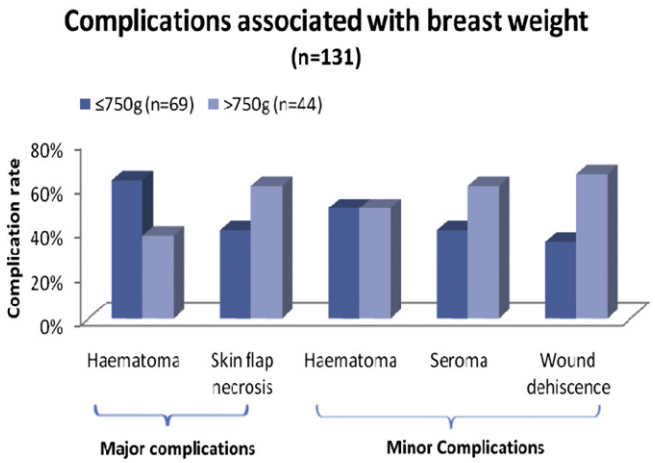

Graph 5. Complications associated with excised breast weight of greater or less than 750 g ($p < 0.01$).

or mastopexy, this is because it affords excellent symmetry[19] as vectoral forces exerted on closed Wise flaps will be similar in bilateral procedures leading to similar descent over time. In our study the mean excised breast mass associated with Wise pattern SSM was 926 g with average SN-N distance of 28.5 cm and 61% of women wearing a D cup or above.

In our study the Wise pattern was associated with significantly more complications than the round incision. These were mainly minor. The main complication associated with the Wise incision was found to be wound dehiscence, especially at the T-junction (32%). There was no correlation between the Wise incision and flap necrosis requiring surgical debridement (12.9% round incision, 10.7% wise pattern).

The main advantages with diathermy dissection appear to be reduced blood loss intra-operatively[20–25] and increased speed of tissue dissection.[18,19,22] Reduction in blood loss appears to be due to immediate coagulation of small vessels in contrast with the oozing that occurs with scalpel incision.[24] This can make the difference between patients requiring transfusion or not. Blood transfusions are associated with transfusion reactions and may be associated with decreased disease free and overall survival in a variety of different tumours possibly due to immunosuppressive effects.[26]

Hoefer et al. (1990)[27] postulated that increased thrombosis of sub-dermal vessels during cauterisation may create relative ischaemia in the tissues of the flaps in addition to inadequately sealed lymphatics which predisposes the wound to seroma formation. This was confirmed by Porter et al. (1998)[23] following modified radical mastectomy and SSM. However, more recent studies have found no correlation.[22,25,28] The results of our study found no correlation between the rates of haematoma in keeping with those of Porter et al. (2007)[23] who looked at the post-operative results of 60 mastectomies. There also does not appear to be any evidence that the use of diathermy causes and significant difference in the rates of post-operative complications as described by Kearns et al. (2001)[21] on their animal models. Several studies have found no correlations following mastectomy[22,23,25] with similar results following midline laparotomy repair.[21,24] The results of this study concur that there is no correlation between diathermy and haematoma, seroma, infection or wound dehiscence when compared with knife dissection technique. This would indicate that the choice of diathermy or blade technique is operator dependent.

Staradub and Morrow (2002)[29] described their infiltrative technique for reducing blood loss associated with knife dissection for modified radical mastectomy. A solution of dilute epinephrine hydrochloride in Ringer's lactate solution was injected subcutaneously allowing rapid dissection with minimal blood loss. Munhoz et al. (2007)[8] had similar experience when injecting a saline/epinephrine solution to facilitate dissecting skin flaps for periareolar SSM. They found the solution allowed a smooth gliding of their instruments and a reduction in bleeding. The vasoconstrictive action of epinephrine, although effective in reducing blood loss, may cause relative ischaemia to the delicate tissues at the edges of the skin flaps especially where the flaps are long and narrow such as in the wise incision and at the T-junction of the tennis incision. Neither study was comparative with the blade technique. In our study there were no correlations between complication rates in any of the categories when comparing those undergoing subcutaneous adrenaline infusion versus no infiltration.

This study found a significant correlation between BMI and complications overall. Flap necrosis and wound dehiscence were significantly higher in women with a BMI of greater than 25 Kg/m^2. This further increased when the BMI rose to 31 Kg/m^2 and over (Diabetics and smokers had been excluded from the study). Interestingly this pattern was not completely mirrored by excised breast mass size. There remained a correlation between increased breast mass and wound dehiscence but not with flap necrosis although there was an association for beasts larger than 1000 g ($p = 0.097$). Increased breast mass may predispose the flaps to skin necrosis due to compromised sub-dermal plexus brought about by the increased surface area of the flap. Women with obesity are likely to have additional complications due to associated microvascular disease. Bra size was recorded in the study but there was no correlation between breast size and the cup size of the bra. Women with a sternal notch to nipple length of less than 26 cm had significantly less complications in general (16% versus 43%, $p = 0.019$) but this failed to reach significance for any particular complication major or minor. This may be attributed to the SN-N length not discriminating between the breast mass and the degree of ptosis.

In our study women had wound dehiscence rates of 6.5% with BMI <26 Kg/m^2, 23% with BMI 26–30 Kg/m^2 and 40% with BMI greater than 30 Kg/m^2. Platt et al. (2003)[14] also found that women with BMI greater than 23 Kg/m^2 developed more complications following wise pattern mastectomy. Wound breakdown rates were 10% for women with BMI less than 23 Kg/m^2 and 26% for those with BMI greater than 23 Kg/m^2. They had excluded women with a BMI of greater than 30 Kg/m^2 but postulated that this group of women would be high risk for wound breakdown. Similar rates were noted when observing the mass of the excised breast tissue. The incidence of wound breakdown was 36% in women with a breast mass of greater than 635 g and 11.4% for breast mass less than 635 g which is comparable with our study where 34% of women with excised breast tissue greater than 750 g and 10.9% less than 750 g experienced wound dehiscence.

Data was not collected on the tumour staging as part of this study, however, patients receiving radiotherapy and chemotherapy had higher rates of major complications and complications in general when compared with the mean, however, this failed to reach significance. There was no difference between the immediate and delayed groups. Gill et al. (2002)[30] found significantly higher rates of fat necrosis in patients requiring radiotherapy. This difference may be a direct correlation between radiotherapy and fat necrosis or may reflect that these women have more advanced cancers, are likely to be immunocompromised and are therefore at higher risk of complications.

Conclusions

Surgical risk factors for SSM include the incision type, with the wise and the tennis incisions having increased wound dehiscence especially around the T-junction region. There is no correlation

between diathermy, knife or infiltrative techniques for soft tissue dissection. Patient related risk factors for complications include increased flap necrosis and wound dehiscence with a BMI of greater than 25 Kg/m^2 and this risk increases as BMI increases. An excised breast mass of greater than 750 g is associated with an overall increase in complications and increased wound dehiscence and an SN-N distance of greater than 25 cm is associated with a general increase in complications.

It is likely that obese women will have greater excised breast mass, a longer SN-N length and are more likely to have a reduction pattern mastectomy such as the wise incision. This would identify them as being at increased risk of complications, both major and minor. In this group of women reconstructive options may be tailored to reduce other risk factors. Ischaemic preconditioning by pre-clamping has been shown to improve flap microcirculation by increasing resistance of the tissues to reoxygenation injury.[31] Two part closure may be considered with a delay in de-epithelialising the free flap for several days until the extent of any tissue necrosis or wound breakdown is apparent. Patients undergoing elective prophylactic mastectomy may benefit from a weight and exercise programme to reduce their BMI before proceeding with surgery.

In conclusion, in a society where increasing numbers of patients have higher body mass indices, the surgeon must consider modification of the skin incision pattern in their pre-operative planning. Wise skin incision patterns should be avoided where possible. Gentle retraction and tissue handling coupled with a round incision pattern and purse stringed closure gives the patient the best chance of successful operative outcome.

Conflict of interest statement

None declared.

References

1. Freemas BS. Subcutaneous mastectomy for benign breast lesions with immediate or delayed prosthetic replacement. *Plastic and Reconstructive Surgery* 1962;**30**:676–82.
2. Toth BA, Lappert P. Modified skin incisions for mastectomy: the need for plastic surgical input in preoperative planning. *Plastic and Reconstructive Surgery* 1991;**87**:1048–53.
3. Kroll SS, Ames F, Singletary EE, Schusterman MA. The oncological risks of skin preservation at mastectomy when combined with immediate reconstruction of the breast. *Surgery, Gynecology, Obstetrics* 1991;**172**:17–20.
4. Bensimon RH, Bergmeyer JM. Improved aesthetics in breast reconstruction: modified mastectomy incision and immediate autologous tissue reconstruction. *Annals of Plastic Surgery* 1995;**34**:229–35.
5. Sotheran WJ, Rainsbury RM. Skin sparring mastectomy in the UK-a review of current practice. *Annals of the Royal College of Surgeons of England* 2004;**86**(2):82–6.
6. Hudson DA. Factors affecting shape and symmetry in immediate breast reconstruction. *Annals of Plastic Surgery* 2004;**52**(1):15–21.
7. Hidalgo DA. Aesthetic refinement in breast reconstruction: complete skin-sparing mastectomy with autogenous tissue transfer. *Plastic and Reconstructive Surgery* 1998;**102**:63–70.
8. Munhoz AM, Aldrighi C, Montag E, Arruda EG, Aldrighi JM, Filassi JR, et al. Periareolar skin-sparing mastectomy and latissimus dorsi flap with bio-dimensional expander implant reconstruction: surgical planning, outcome and complications. *Plastic and Reconstructive Surgery* 2007;**119**:1637–49.
9. Meretoja TJ, von Smitten KAJ, Kuokkanen HOM, Suominen SHH, Jahkola TA. Complications of skin-sparing mastectomy followed by immediate breast reconstruction. *Annals of Plastic Surgery* 2008;**60**(1):24–8.
10. Carlson GW, Bostwick J, Styblo TM, Moore B, Bried JT, Murray D, et al. Skin sparring mastectomy: oncologic and reconstructive considerations. *Annals of Surgery* 1997;**225**:570–8.
11. Kroll SS, Khoo A, Singletary SE, Ames FC, Wang BG, Reece GP, et al. Local recurrence risk after skin sparing and conventional mastectomy: a 6 year follow-up. *Plastic and Reconstructive Surgery* 1999;**104**:421–5.
12. Georgiade G, Georgiade N, McCarty KS, Seigler HF. Rationale for immediate reconstruction of the breast following modified radical mastectomy. *Annals of Plastic Surgery* 1982;**8**:20–8.
13. Singletary SE. Skin sparing mastectomy with immediate breast reconstruction: the MD Anderson cancer institute experience. *Annals of Surgical Oncology* 1996;**3**:411–6.
14. Platt AJ, Mohan D, Baguley P. The effect of body mass index and wound irrigation on outcome after bilateral breast reduction. *Annals of Plastic Surgery* 2003;**6**:552–5.
15. Nahabedian MY, Momen B, Galdino G, Manson PN. Breast reconstruction with the free TRAM or DIEP flan: patient selection, choice of flan, and outcome. *Plastic and Reconstructive Surgery* 2002;**110**(2):466–750.
16. Kroll SS. Fat necrosis in free transverse rectus abdominis myocutaneous and deep inferior epigastric perforator flaps. *Plastic and Reconstructive Surgery* 2000;**106**:576–83.
17. Hamdi M, Weler-Mithoff EM, Webster MHC. Deep inferior epigastric perforator flap in breast reconstruction: experience with the first 50 flaps. *Plastic and Reconstructive Surgery* 1999;**103**(1):86–95.
18. Rainsbury RM. Skin-sparing mastectomy. *British Journal of Surgery* 2006;**93**:276–81.
19. Skoll PJ, Hudson DA. Skin-sparing mastectomy using a modified wise pattern. *Plastic and Reconstructive Surgery* 2001;**110**(1):214–7.
20. Demirkan F, Gurbuz O, Tutuncu N, Akca T, Aydun S. Use of wise pattern for achieving symmetry in one stage in immediate reconstructions with deep inferior epigastric artery perforator flap. *Annals of Plastic Surgery* 2006;**56**(4):359–63.
21. Kearns SR, Connolly EM, McNally S, McNamara DA, Deasy J. Randomized clinical trial of diathermy versus scalpel incision in elective midline laparotomy. *British Journal of Surgery* 2001;**88**:41–4.
22. Kurtz SB, Frost DB. A comparison of two surgical techniques for performing mastectomy. *European Journal of Surgical Oncology* 1995;**21**:143–5.
23. Porter KA, O'Connor S, Rimm E, Lopez M. Electrocautery as a factor in seroma formation following mastectomy. *The American Journal of Surgery* 1998;**176**:8–11.
24. Telfer JRC, Canning G, Galloway DJ. Comparative study of abdominal incision techniques. *British Journal of Surgery* 1993;**80**:233–5.
25. Rodd CD, Velchuru VR, Holly-Archer F, Clark A, Pereira JH. Randomized clinical trial comparing two mastectomy techniques. *World Journal of Surgery* 2007;**31**:1164–8.
26. Kerin MJ, O'Hanlon DM, Kenny P, Kent PJ, Given HF. Argon-enhanced cutting and coagulation confers advantages over conventional electrocautery for mastectomy. *European Journal of Surgical Oncology* 1996;**22**:571–3.
27. Hoefer RA, Dubois JJ, Ostrow LB, Silver LF. Wound complications following modified radical mastectomy: an analysis of perioperative factors. *JAOA* 1990;**90**:47–53.
28. Nadkarni MS, Rangole AK, Sharma RK, Hawaldar RV, Parmar VV, Badwe RA. Influence of surgical technique on axillary seroma formation: a randomized study. *ANZ Journal of Surgery* 2007;**77**:385–9.
29. Staradub VL, Morrow M. Modified radical mastectomy with knife technique. *Archives of Surgery* 2002;**137**:105–10.
30. Gill PS, Hunt JP, Guerra AB, Dellacroce FJ, Sullivan SK, Boraski J, et al. A 10 year retrospective review of 758 DIEP flaps for breast reconstruction. *Plastic and Reconstructive Surgery* 2002;**113**(4):1153–60.
31. Harder Y, Amon M, Laschke MW, Schramm R, Rucker M, Wettstein R, et al. An old dream revitalised: preconditioning strategies to protect surgical flaps from critical ischaemia and ischaemia-reperfusion injury. *Journal of Plastic and Reconstructive Surgery* 2008;**61**:503–11.