Injury, Int. J. Care Injured 45 (2014) 1900–1907

Contents lists available at ScienceDirect

Injury

journal homepage: www.elsevier.com/locate/injury

Clinical results of acetabular fracture management with the Pararectus approach

Marius Johann Baptist Keel [a], Salvatore Tomagra [a], Harald Marcel Bonel [b], Klaus Arno Siebenrock [a], Johannes Dominik Bastian [a,*]

[a] Department of Orthopaedic and Trauma Surgery, University of Bern, Inselspital, Freiburgstrasse 3, 3010 Bern, Switzerland
[b] Institute for Diagnostic, Interventional and Paediatric Radiology, University of Bern, Inselspital, Freiburgstrasse 3, 3010 Bern, Switzerland

ARTICLE INFO

Article history:
Accepted 14 October 2014

Keywords:
Acetabular fracture
Pararectus approach
Stoppa approach
Outcome
Dome Impaction
Quadrilateral Plate
Reduction

ABSTRACT

Introduction: To present the accuracy of reduction, complications and results two years after open reduction and internal fixation of displaced acetabular fractures involving the anterior column (AC) through the Pararectus approach. Frequencies for conversion to total hip replacement in the early follow up, the clinical outcome in preserved hips, and the need for an extension of the approach (1st window of the ilioinguinal approach) are compared to the literature about the modified Stoppa approach.
Methods: Forty-eight patients (mean age 62 years, range: 16–98; 41 male) with displaced acetabular fractures involving the AC (AC: $n = 9$; transverse fracture: $n = 2$; AC and hemitransverse: $n = 24$; both column: $n = 13$) were treated between 12/2009 and 12/2011 using the Pararectus approach. Surgical data and accuracy of reduction (using computed tomography) were assessed. Patients were routinely followed up at eight weeks, 6, 12 and 24 months postoperatively. Failure was defined as the need for total hip arthroplasty. Twenty-four months postoperatively the outcome was rated according to Matta.
Results: In four patients there were four intraoperative complications (minor vascular damage in two, small perforations of the peritoneum in two) which were managed intraoperatively. Fracture reduction showed statistically significant decreases (mean ± SD, pre- vs. postoperative, in mm) in "step-offs": 2.6 ± 1.9 vs. 0.1 ± 0.3, $p < 0.001$ and "gaps": 11.2 ± 6.8 vs. 0.7 ± 0.9, $p < 0.001$. Accuracy of reduction was "anatomical" in 45, "imperfect" in three. Five (13%) from 38 available patients required a total hip arthroplasty. Of 33 patients with a preserved hip the clinical outcome was graded as "excellent" in 13 or "good" in 20; radiographically, 27 were graded as "excellent", four as "good" and two as "fair". An extension of the approach was infrequently used (1st window ilioinguinal approach in 2%, mini-incision at the iliac crest in 21%).
Conclusion: In the treatment of acetabular fractures involving the anterior column the Pararectus approach allowed for anatomic restoration with minimal access morbidity. Results obtained by means of the Pararectus approach after two years at least parallel those reported after utilisation of the modified Stoppa approach. In contrast to the modified Stoppa approach, a relevant extension of the Pararectus approach was almost not necessary.

Introduction

The anatomical restoration of the acetabular joint surface in the treatment of displaced acetabular fractures has been deemed to be essential if failure of joint-preserving surgery is to be avoided [1–3]. However, anatomic reduction is becoming increasingly cumbersome as the appearance of fractures has altered (e.g. impaction of the superomedial acetabular roof), mainly as a result of an observed increase in geriatric trauma [2,4–6]. A further impact on the outcome was related to access morbidity [7] which might be of particular importance in the elderly with restricted physiological reserves.

The ilioinguinal approach [8] is the "gold standard" for treatment of acetabular fractures involving the anterior column. However, the ilioinguinal approach might be suboptimal due to the access morbidity on account of the extended access. Therefore, others have reported the modified Stoppa approach as a less invasive alternative for the surgical access [9–19]. Recently,

* Corresponding author. Tel.: +41 (0)31 632 2111; fax: +41 (0)31 632 3600.
E-mail address: johannes.bastian@insel.ch (J.D. Bastian).

http://dx.doi.org/10.1016/j.injury.2014.10.040

anatomic reduction was achieved more frequently by utilisation of the modified Stoppa approach compared to the ilioinguinal approach [20] as well as a reduced intraoperative blood loss and a shortened operative time [21].

Also, the Pararectus approach has been introduced as a less-invasive, single-incision approach which combines the advantages of the "second and third windows" of the ilioinguinal approach with the medial view of the modified Stoppa approach [22]. It was hypothesised that the results obtained by utilisation of the new Pararectus approach parallel or even exceed those achieved by the use of the modified Stoppa approach in acetabular fracture surgery. Thus, the aims of the report is to present the obtained results after two years, collected prospectively, following acetabular fracture fixation using the Pararectus approach with focus on (1) the frequencies for conversion to total hip replacement in the early follow up, (2) the clinical outcome in preserved hips and (3) to compare these data as well as associated surgical access morbidity (in terms of intra- and postoperative complications and the necessity to extend the surgical access by the use of the first window of the ilioinguinal approach) to those reported in the existing literature after utilisation of the modified Stoppa approach.

Table 1
Patients' demographics, mechanisms of injury, fracture classifications and characteristics in a series of 48 patients (mean ± standard deviation (range) or number (percentage)).

Parameter	Value
Age (years)	62 ± 18 (16–98)
Age ≥ 60 (years)	26 (54)
Male gender	41 (85)
Body mass index (kg/m^2)	24 (18–30)
Mechanism of injury	
MVC	8 (17)
Sports	14 (29)
Fall > 2 m	7 (15)
Low energy trauma (fall < 2 m)	19 (40)
Fracture classification (elementary patterns)	11 (23)
Anterior column (AC)	9 (19)
Transverse (Tr)	2 (4)
Fracture classification (associated patterns)	37 (77)
Anterior column with posterior hemitransverse (ACPHT)	24 (50)
Both column (BC)	13 (27)
Fracture characteristics	
Quadrilateral plate displacement	37 (77)
Acetabular dome fragment	27 (56)
Femoral head impaction	12 (25)
Initial fracture displacement ≥ 20 mm	5 (10)

Methods

Patients

This study was approved by our local institutional review board. Patients presenting with acetabular fracture patterns as described by Judet et al. [8] that would have been treated previously at our institution using a combination of the modified Stoppa approach [11,18] and the first window of the ilioinguinal approach [23] (anterior column (AC) with or without posterior hemitransverse fractures (ACPHT), transverse (Tr), both column (BC) fractures) were treated surgically using the Pararectus approach [22]. A consecutive series of 59 patients (mean age 63 years, range: 16–98; 47 male) was treated between 12/2009 and 12/2011. Patients presenting with fracture patterns requiring an additional posterior approach ($n = 6$), a history of previous surgery ($n = 2$), severe osteoarthritis requiring fracture fixation in combination with a total joint replacement ($n = 2$) or a pathologic fracture as a result of advanced tumour disease ($n = 1$) in the operated hip joint were omitted. A series of 48 patients (mean age 62 years, range: 16–98; 41 male) were included, with displaced acetabular fractures involving the anterior column being treated using the Pararectus approach [22] as a single approach. Patients' demographics, including body mass index (kg/m^2), injury mechanisms, fracture classifications (according to Judet et al. [8]), occurrence of specific fracture characteristics (as assessed on preoperative CT scans) are presented in Table 1.

Surgical technique

Patients were placed in the supine position on a radiolucent operating table. C-arm fluoroscopy was used to assess accuracy of reduction and implant location intraoperatively. The limb was draped free to allow for intraoperative reduction manoeuvers. The skin was incised along the lateral border of the rectus abdominis muscle, the rectus sheath was developed and incised to enter the extraperitoneal space as described previously [22]. In the cephalad-caudad direction, the iliac and psoas muscles, the external iliac artery and vein (vascular bundle), the vas deferens in males or the round ligament in females, the inferior epigastric vessels, the obturator vessels and nerve as well as the vascular anastomosis between the epigastric or external iliac and obturator vessels were identified. For instrumentation on the pelvic brim and/or on the quadrilateral plate, the iliopectineal fascia was incised, the pectineus muscle partially released and mobilised laterally and/or the obturator muscle was detached from the quadrilateral plate, respectively. The iliopsoas muscle and the vascular bundle were encircled using a silastic sling for safe retraction to develop the area between the iliopsoas muscle and the vascular bundle (2nd window), the vascular bundle and the vas deferens or round ligament with the inferior epigastric vessels (3rd window), the vas deferens or round ligament with the inferior epigastric vessels and the pubic symphysis (4th window). The 5th window was similar to the 3rd window in terms of the borders, but located deeper within the true pelvis, below the pelvic brim and provided an intraoperative view comparable to that provided by the modified Stoppa approach [11,18]. A separate mini-incision (1–5 cm) above the anterior superior iliac spine without detachment of the iliacus muscle might become necessary to complete an incomplete high anterior column fracture, for placement of reduction clamps (e.g. Faraboeuf clamp, Schanz screws) for reduction manoeuvers (e.g. internal rotation of the hemipelvis) or positioning of lag screws for fixation of high anterior column fractures exiting the iliac crest. The difference in the intrapelvic visualisation using the Pararectus approach has been opposed to that obtained by the modified Stoppa approach in Fig. 1.

Where a degenerative hernia was an incidental finding intraoperatively, the hernia was revised using an extraperitoneal mesh. In patients with a history of previous hernia repair using a mesh, the mesh was easily detached at its cranial border instead of being dissected.

For fracture fixation, 3.5 mm diameter cortical screws and reconstruction plates placed on the pelvic brim were used. In fractures with medial displacement of the quadrilateral plate, a medial buttress plate was placed infrapectineally as recommended previously [24,25]. Intravenous antibiotic prophylaxis was administered (1.5 g cefuroxime, three times daily for a minimum of two postoperative days). As an antithrombotic prophylaxis, self-administered subcutaneous low-molecular weight heparin was provided daily until the patient was mobile. Patients were allowed toe-touch weight-bearing for the first eight weeks before proceeding to full weight-bearing after radiological evidence of fracture consolidation was seen.

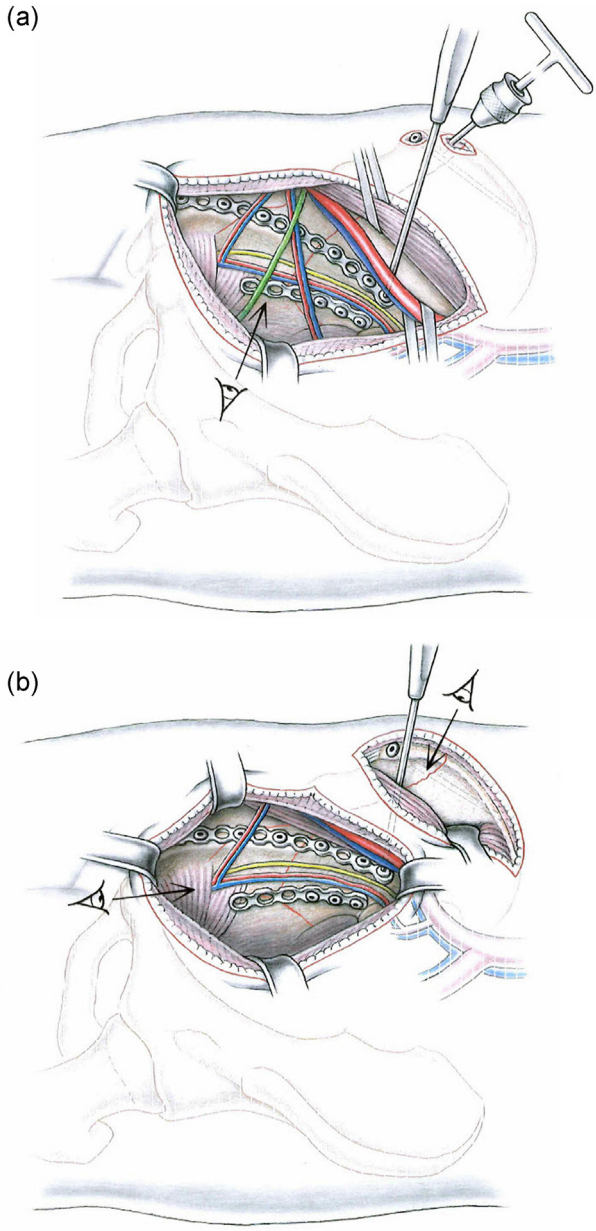

Fig. 1. (a) Schematic drawing showing the surgical exposure using the Pararectus approach lateral to the rectus abdominis. An additional mini-incision (1–5 cm) above the anterior superior iliac spine was used infrequently for placement of reduction clamps and/or positioning of lag screws. There was no need to change the surgical window nor the position of the surgeon. (b) Schematic drawing showing the surgical exposure using the modified Stoppa approach and potential limitations in the access to the 2nd window between the iliopsoas muscle and the vascular bundle (e.g. in plate fixation at the posterior pelvic brim, posterior column screws). The combination with a true 1st window of the ilioinguinal approach with large incision and detachment of the iliacus muscle is frequently used.

Evaluation

The surgical data (delay to surgery, operative time, blood loss, length of incision, intraoperative and postoperative complications, frequencies for the need to extend the Pararectus approach) were assessed. Various covariates (age, high energy trauma, initial fracture displacement $\geq$ 20 mm, quadrilateral plate displacement, associated fracture type, operating time) were considered as a high predilection for a high blood loss and analysed accordingly. The frequencies to encounter degenerative hernias intraoperatively, the amount of patients with a history of inguinal hernia repair and of patients suffering from symptomatic hernia related to the approach were evaluated. Evaluation of pre- vs. postoperative fracture displacement ("step-off", "gap"), displacement of the femoral head ("cranialisation", "medialisation") and the accuracy of reduction (anatomical: <1 mm "step-off", imperfect: 1–3 "step-off", poor: >3 mm "step-off") was performed using CT scans with axial, coronal and sagittal planes as described previously [22].

Patients were routinely followed up at eight weeks, and 6, 12 and 24 months postoperatively. The need for total hip replacement in the early postoperative course after an attempt at joint-preserving surgery was assessed. Frequencies of various parameters (age, gender, trauma mechanism, fracture type, fracture characteristics: quadrilateral plate displacement, acetabular dome fragment, femoral head impaction, initial fracture displacement $\geq$ 20 mm, postoperative accuracy of reduction: Residual "Step-off " > 1 mm, residual "Gap" > 2 mm) were compared between patients requiring a conversion to a total hip replacement and patients with preserved hips during follow up.

Clinically, the Harris Hip Score [26,27], the Merle d'Aubigné and Postel grading [28] (adapted by Matta [29,30]), the Western Ontario McMasters (WOMAC) Score [31] were used. The patients' general health status [32] and the activity status [33] were assessed. Radiographically, for assessment of the occurrence of osteoarthritis (OA), heterotopic ossifications (HO) or avascular femoral head necrosis (AVN) according to Tönnis [34], Brooker [35], and Ficat [36] classifications respectively, conventional radiographs were used. In addition, clinical and radiographic outcome was rated according to Matta [29]. The outcome at two years postoperatively of patients unable to be evaluated at the outpatient clinic (e.g. suffering from dementia, parkinsonism or multiple medical comorbidities) was enquired about in a telephone interview with their relatives and/or their family doctors. Patients with an activity level comparable to their pre-injury level without any analgesic medication, no subsequent surgery and no total hip arthroplasty to the operated hip joint so far were categorised as "doing well".

Statistical analysis

The Wilcoxon signed-rank test was used to compare fracture displacement on pre- and postoperative CT scans. The Fisher exact test was used for comparison of categorical data, the Wilcoxon rank sum test was applied for comparison of continuous data. A multivariate linear regression analysis was performed to identify predictors for high blood loss. The analysed co-variates were age, high energy trauma, initial fracture displacement $\geq$ 20 mm, quadrilateral plate displacement, associated fracture type and operating time. Level of significance set at $\alpha < 0.05$. Analyses were performed with SAS 9.3 (SAS Institute Inc., Cary, NC, USA).

Results

In the included 48 patients, the mean delay to surgery was five days (SD 3; range: 0–17), the mean operating time 200 min (SD 64; range: 50–363), the mean length of the incision 11 cm (SD 3; range: 6–20), the mean blood loss 1477 ml (SD 1172; range: 100–6000; in 33% of operated cases at least 2000 ml or higher). No multivariate predictor for high blood loss was identified. Occurrence of "Quadrilateral plate displacement" was associated by tendency with high blood loss ($p = 0.056$; Table 2). Patients without quadrilateral plate displacement showed a blood loss of 782 ± 512 (300–2000) whereas patients presenting with a quadrilateral plate displacement had a blood loss of 1684 ± 1237 (100–6000). The observed difference was statistically significant ($p = 0.016$).

In one patient (2%) utilisation of the 1st window of the ilioinguinal approach became necessary for fixation of a high

Table 2
Multivariate linear regression analysis to identify predictors for a high blood loss in 48 patients included to the study.

Parameter	*p*-value
Age ≥ 60 years (yes/no)	0.382
High energy mechanism (yes/no)	0.516
Initial fracture displacement ≥ 20 mm (yes/no)	0.387
Quadrilateral plate displacement (yes/no)	0.056
Associated fracture type (yes/no)	0.843
Operating time (in min)	0.382

anterior column fracture exiting the iliac crest far posterior, in four patients (8%) the 1st window of the Pararectus approach was required and in ten (21%) a mini-incision at the iliac crest was necessary (in five for reduction only, in five for reduction and placement of a screw or plate).

In four patients of 48 (8%) there were four intraoperative complications (minor vascular damage in two, small perforations of the peritoneum in two) which were managed intraoperatively. A degenerative hernia was found as an incidental finding in one patient (2%) and revised within the operation. Seven of 48 (15%) patients (mean age 77 years, range: 64–90) had a history of previous hernia repair, however, dissection within this area was without difficulty as the mesh was easily detached. No patient presented with a hernia during follow up.

In one elderly patient (73 years) who sustained a both-column fracture after a skiing accident, wound healing was complicated by a superinfected (*Streptococcus agalactiae*) retroperitoneal hematoseroma two months postoperatively. After hardware removal, debridement and administration of antibiotics, the wounds healed and fracture union occurred uneventfully. According to the Matta grading the patient was graded as "good" clinically and as "excellent" radiographically 24 months postoperatively.

As measured using CT scans, the mean "step-off" was statistically significantly decreased by fracture reduction from 2.6 mm (SD 1.9; range: 0.2–8.6) preoperatively to 0.1 mm (SD 0.3; range: 0.0–1.3) postoperatively ($p < 0.001$). The mean "gap" was statistically significant decreased by fracture reduction from 11.2 mm (SD 6.8; range: 1.0–30.0) preoperatively to 0.7 mm (SD 0.9; range: 0.0–3.6) postoperatively ($p < 0.001$). Details of the radiological evaluation are presented in Table 3. In summary, the accuracy of reduction was "anatomical" in 45 patients (e.g. Fig. 2) and "imperfect" in three patients using "step-off" analysis in the weight-bearing area on postoperative CT scans.

Two years postoperatively, four patients were lost to follow-up (one was discharged overseas and three died; one at 2, one at 11 and one at 19 months postoperatively). A further six patients (mean age 76 years, range: 66–89) refused consultation, but could be categorised as "doing well" on telephone interview. From the remaining 38 (79%) patients, five (13%) required a total hip

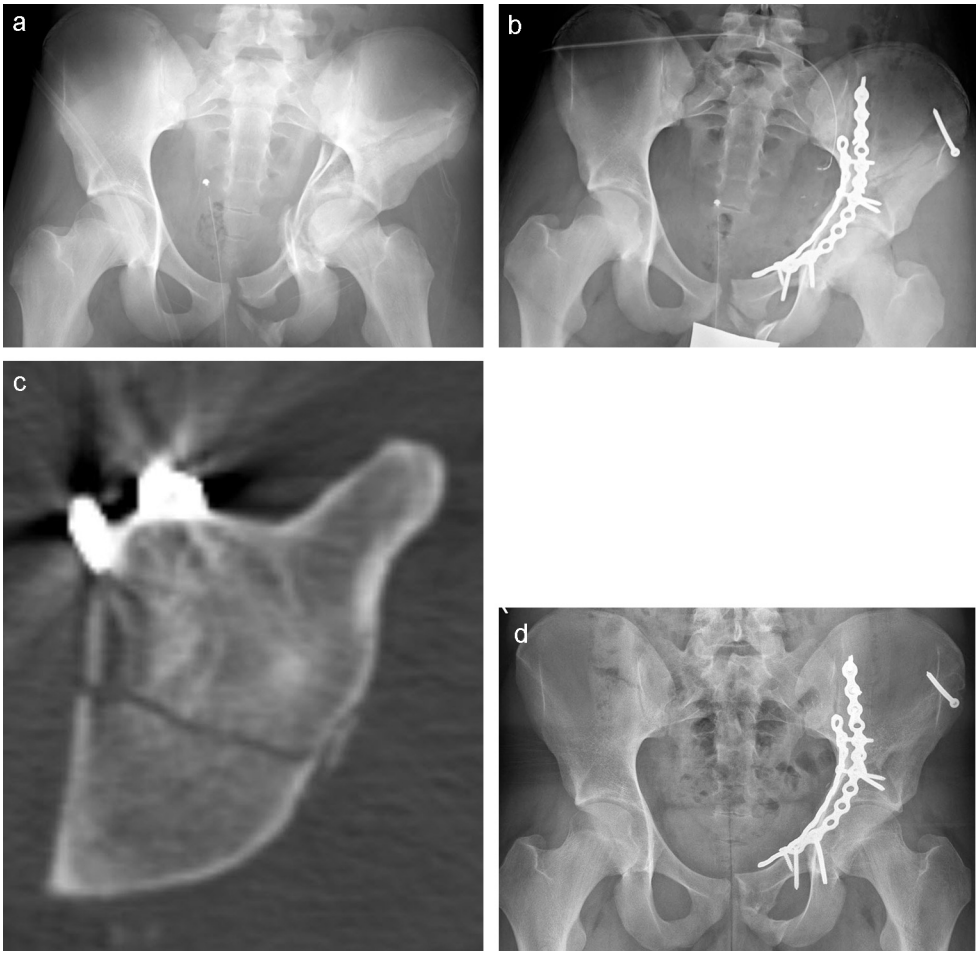

Fig. 2. (a) Anteroposterior radiograph of a 16-year-old patient who sustained a both column acetabular fracture due to a skiing accident. The pre-operative image is shown. (b) Anteroposterior radiograph presenting the postoperative image with no residual displacement after fracture reduction and fixation. (c) Postoperative axial CT scan at the level of the acetabular dome presenting anatomic reduction, with a gap of 1–2 mm. (d) Anteroposterior radiograph 2.5 years after surgery. No signs of posttraumatic osteoarthritis are observed, the radiological status at the latest follow-up was scored as "excellent" according to the Matta criteria.

Table 3
Radiological evaluation of acetabular fracture displacement in a series of 48 patients included to the study (mean and standard deviation (SD)).

Parameter	Preoperative	Postoperative	*p*-value
Mean (SD) maximal step-off			
Axial	2.7 (2.0)	0.1 (0.4)	<0.001*
Coronal	2.7 (2.4)	0.1 (0.4)	<0.001*
Sagittal	2.4 (2.1)	0.1 (0.2)	<0.001*
Mean (SD) maximal gap			
Axial	11.5 (7.6)	0.9 (1.2)	<0.001*
Coronal	11.3 (7.5)	0.7 (1.0)	<0.001*
Sagittal	10.8 (7.8)	0.6 (1.1)	<0.001*
Mean (SD) femoral head displacement			
Medialisation	9.0 (6.6)	1.2 (1.4)	<0.001*
Cranialisation	7.2 (6.8)	1.9 (4.0)	<0.001*

* Wilcoxon's signed ranks test for paired groups.

arthroplasty at a mean of 12 months postoperatively (range: 4–22). An acetabular dome fragment was more frequently observed with statistical significance in patients with conversion to a total hip replacement ($p = 0.046$; Table 4, e.g. Fig. 3).

In patients with a preserved hip the outcome at 24 months postoperatively was as follows: The mean score was 88 (SD 12; range: 61–100) for the Harris Hip-, 17 (SD 1; range: 14–18) for the Merle d'Aubigné-, 9 (SD 11; range: 0–46) for the WOMAC-, 7 (SD 3; range: 2–10) for the UCLA-, 50 (SD 8; range: 33–62) for the SF12 "physical" and 56 (SD 5; range: 46–66) for the SF12 "mental" score. Radiographically, no (Tönnis grade: 0, $n = 27$), mild (Tönnis grade: 1; $n = 4$) or moderate (Tönnis grade: 2; $n = 2$) signs of osteoarthritis were noticed. Avascular necrosis was not observed. Heterotopic bone formation was observed in one patient (Brooker class 2), however, without any significant impact on the range of motion (96% of the value of the contralateral hip). According to Matta, two years postoperatively in patients with a preserved hip the outcome was rated as "excellent" in 13 and "good" in 20, clinically or "excellent" in 27, "good" in four and "fair" in two patients radiographically.

Discussion

The Pararectus approach was introduced for treatment of acetabular fractures involving the anterior column. The main suggested advantage in comparison to established procedures was to simplify the treatment of specific fracture patterns with less invasive tissue dissection, while being at the same time in the hands of experienced acetabular surgeons [22]. The Pararectus approach provided access to the area of interest from a more medial position. Additionally, application of reduction forces along the pelvic brim contrariwise to the trauma forces in line with the direction of the dislocation, the dissection in the "middle window" of the ilioinguinal approach is avoided and the incision length reduced. However, to what extent the use of the new approach might improve the outcome at the midterm in comparison to other less invasive approaches was unclear, so this study was initiated.

The most significant failure might be conversion to total joint replacement in the early postoperative course after an attempt at joint-preserving surgery, due to morbidity, especially in the elderly. However, primary total hip arthroplasty was not generally recommended for acetabular fractures by others [37] and the risk for acetabular cup loosening requiring revision in cases of distinct displacement is a concern [5]. In the presented report, in five patients (13% of all cases), total hip replacement was performed during the early follow-up period of two years. All of these patients presented with an acetabular dome fragment. In one patient, an additional significant femoral head impaction (previously identified as being a predictor of poor outcome – inter alia prosthetic replacement of the hip [3,6,7,38]) might have led to severe osteoarthritis requiring a total hip arthroplasty. The presented results agree with the literature in cases of utilisation of the modified Stoppa approach where the conversion rate to total joint replacement was reported to be in the range of 0–17% [9–13,15,17,19,21].

At a minimum follow-up of two years, patients with preserved hips presented with "excellent" or "good" clinical outcome and the obtained radiographic outcome was "excellent" or "good" in 94% of patients. In two patients the radiographic outcome was reported as "fair". This included a 54-year-old patient where joint degeneration (Tönnis grade: 2) was already preexisting on the initial radiographs and was rather related to severe cam type deformity than to the fracture and/or fracture management, the patient did not show any symptoms (clinically graded as "excellent"). The other patient was a 50-year-old, where joint degeneration (Tönnis grade: 2) occurred in the injured hip joint during follow-up after anatomic reduction and fixation of an anterior column with posterior hemitransverse fracture associated with a displaced acetabular dome fragment, a femoral head impaction, breakout of the quadrilateral plate and distinct initial fracture displacement (≥20 mm). However, clinically the patient presented with an excellent result at a high activity level (UCLA Score: 10), indicating an asymptomatic osteoarthritis.

Table 4
Comparison of categorical and continuous data in patients requiring a conversion to a total hip replacement ("THR patients") and patients with preserved hips ("non THR patient") during follow up in 38 remaining patients at two years postoperatively.

Parameter	THR patients ($n = 5$)	Non-THR patients ($n = 33$)	Comparison (*p*-value)	Overall ($n = 38$)
Age (mean ± SD; years)	66 ± 15	57 ± 19	0.320*	58 ± 18
Age ≥ 60 years (%)	60	42	0.640‡	45
Male gender (%)	60	88	0.170‡	84
High energy trauma (%)	80	67	1.000‡	68
Anterior column (AC) (%)	0	24	0.560‡	21
Transverse (Tr) (%)	0	6	1.000‡	5
Anterior column with posterior hemitransverse (ACPHT) (%)	80	36	0.140‡	42
Both column (BC) (%)	20	34	1.000‡	32
Quadrilateral plate displacement (%)	80	79	1.000‡	79
Acetabular dome fragment (%)	100	42	0.046‡	50
Femoral head impaction (%)	40	21	0.570‡	24
Initial fracture displacement ≥ 20 mm (%)	20	9	0.450‡	11
Residual "Step-off" > 1 mm (%)	20	3	0.250‡	5
Residual "Gap" > 2 mm (%)	20	18	1.000‡	18

* Wilcoxon rank sum test.
‡ Fisher exact test.

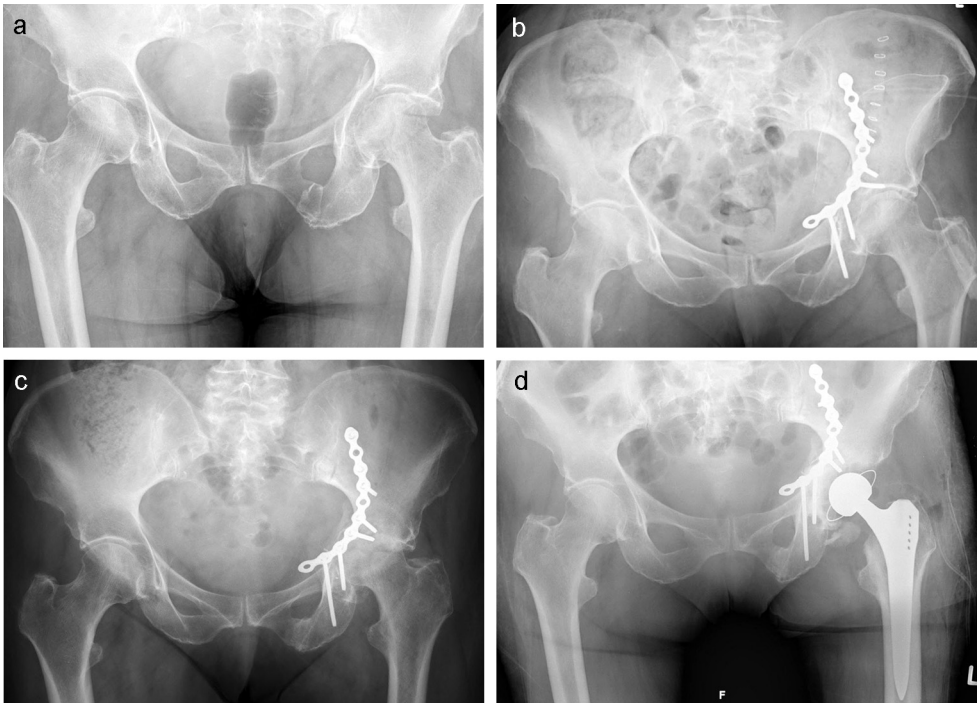

Fig. 3. (a) Anteroposterior radiograph of a 78-year-old patient who sustained an acetabular fracture of the anterior column with posterior hemitransverse, medial displacement of the quadrilateral plate, central displacement of the femoral head, impaction of the acetabular dome ("gull" sign) and of the femoral head due to low-energy fall. The pre-operative image is shown. (b) Anteroposterior radiograph presenting the postoperative image with anatomic fracture reduction with desimpaction of the osteochondral acetabular dome fragment using the femoral head as a template, filling of the defect with synthetic bone and definitive fracture fixation. (c) Anteroposterior radiograph 4 months after surgery. An acetabular dome fragment and an impaction fracture of the femoral head might have resulted in severe posttraumatic osteoarthritis with poor radiographic grading according to the Matta criteria at the early follow-up. (d) Anteroposterior radiograph 4 months after surgery. Due to severe posttraumatic osteoarthritis revision surgery was necessary with conversion to a total hip replacement at this time point.

The presented outcome obtained using the Pararectus approach is at least be comparable to that obtained with utilisation of the modified Stoppa approach for acetabular fracture management. In these cases "excellent" or "good" clinical results at a minimum follow-up of one year are reported within the range of 63–89% [10–13,15,17,19,21]. The access morbidity in our series was acceptably low with only four (8%) minor intraoperative complications, one (2%) postoperative wound healing disorder and no postoperative hernias. The risk of peritoneum perforation during surgical dissection might be increased in the presence of minor adhesions between the transversalis fascia and the peritoneal sac. Higher blood loss was by tendency associated with displacement of the quadrilateral plate.

The presentation of the outcome data at two years might be crucial for establishing the new approach, as the observed median time to failure was 1.5 years [3]. Although the comparison to others might be hindered due to differences in the frequencies and distributions of fracture patterns, additional fracture characteristics, patients' age, follow-up periods, description of drop-outs and losses to follow-up as well as variations in the used outcome measures, the presented data provide evidence that the two-year results of open reduction and internal fixation of acetabular fractures through the Pararectus approach parallel the previously published results when standard approaches are utilised. The presented study provides a detailed analysis of the acetabular fractures, the accuracy of reduction using CT scans pre- and postoperatively and a prospective protocol to assess the outcome.

The main benefit of the Pararectus approach over the modified Stoppa approach might be its utilisation as a single incision approach avoiding the "superficial" dissection in the "middle window" and decreasing the incision length, but allowing medial access through the 5th window to the true pelvis (with a view comparable to the modified Stoppa approach). An extension of the approach was infrequently used (1st window ilioinguinal approach in 2%, mini-incision at the iliac crest in 21%) whereas the modified Stoppa approach was frequently used with the combination of the 1st window of the ilioinguinal approach [8] (55–93% [10,14,17,19–21]) or others [9,13,15] described this combination as their standard procedure. Furthermore, the Pararectus approach allows (1) clear visualisation of the fracture without the need to change either the surgical window or the position, (2) access to the anterior wall, (3) secure access to the 2nd window, and facilitates (4) a skin incision in cases with suprapubic bladder catheters in situ (one patient in the presented series) or (5) various directions of posterior column screws without the need for an additional 1st window of the ilioinguinal approach. The advantages of the Pararectus approach compared to the modified Stoppa approach as well as the major and minor indications for utilisation of the Pararectus approach – in our hands – in relation to the detailed fracture morphology are highlighted in Tables 5 and 6, respectively.

Advantages of the Pararectus approach compared to the extrapelvic ilioinguinal approach are (1) avoidance of an iatrogenic inguinal hernia, (2) no dissection of the inguinal canal, (3) simplified surgical dissection in cases where an inguinal hernia has previously been repaired or reinforced with a mesh or degenerative hernias are encountered intraoperatively, (4) less traction injuries to the lateral cutaneous nerve, as excessive traction is not necessary, (5) medial view on the quadrilateral plate, (6) a simplified wound closure (the fasciae of the rectus and externus abdominis muscles only need to be sutured to complete closure of the approach).

A limitation of the presented report might be that the statistical analysis to assess predictive factors for conversion to total hip replacement during follow up or to identify a high predilection for blood loss might be limited by the low number of cases.

Table 5
Advantages and disadvantages of the Pararectus approach in comparison to the modified Stoppa approach.

Criteria	Pararectus	Modified Stoppa
Utilisation as a single approach (no change of windows)	+	– (1st window of ilioinguinal (II) approach)
Decreased incision length	+	– (often additional 1st window of II)
Directions of posterior column screws		
– Infraacetabular	+	+ (limited)
– Along the quadrilateral plate	+	– (1st window of II is needed)
Open reduction and internal fixation of quadrilateral plate (buttress plate)	+	+
Desimpaction and bone grafting of dome fragment	+	+
Open reduction and internal fixation of displaced sacroiliac joint	+	– (1st window of II is needed)
Vascular control		
– Corona mortis	+	+
– External iliac vessels	+	– (limited)
– Internal iliac vessels	+	–
– Iliolumbal vessels	+	–
Risk for peritoneal lesion	–	(–)
Use in cases with inguinal hernia (additional hernia repair (mesh))	+	– (limited)
Use in cases with previous hernia repair with mesh	+	– (limited)
Use after suprapubic bladder catheter	+	–
Use in obese patients	?	?

"+" = advantage; "–" = disadvantage; "?" = unkown.

Table 6
Indications of Pararectus or modified Stoppa approaches or their modifications for the management of acetabular fracture patterns involving the anterior column (anterior wall (AW), anterior column (AC), transverse (Tr), anterior column with posterior hemitransverse (AC + PHT), T-shaped (T), both column (BC)) in relation to the detailed fracture morphology.

Fracture morphology	Pararectus	Modified Stoppa
Anterior wall (AW)		
– Pure AW	+	–
– AW + AC (involvement of quadrilateral plate)	+	(+) limited
Anterior column (AC)		
– Very low	+	+
– Low	+	+
– Intermediate	+	–
– High: – simple	With mini-incision or 1st window of Pararectus approach (P)	With 1st window of ilioinguinal approach (II)
– Comminuted	With 1st window of II	With 1st window of II
– With involvement of sacroiliac joint	+	With 1st window of II
Pure transverse (Tr) (main dislocation in anterior column)	+	+ (with 1st window of II)
Anterior column with posterior hemitransverse (AC + PHT)	+ (in high anterior column component with mini-incision or 1st window of P)	+ (in high anterior column component with 1st window of II)
Anterior T-shaped (T)	+	With 1st window of II
Both column (BC)		
– Extending to iliac crest or incomplete fracture	With mini-incision or 1st window of P	With 1st window of II
– Extending to anterior border of ilium	+	-
– With involvement of sacroiliac joint	+	With 1st window of II
– With fracture of posterior wall (PW)	With percutaneous screw or posterior approach	With percutaneous screw or posterior approach

"+" = indication; "–" = contraindication.

Additionally, we cannot provide any experience with the new approach in obese patients. As such obesity might be a limitation of the new approach. Finally, the "loss" of six patients who were assessed by telephone interview only, although, categorised as "doing well" is a potential limitation. The noted availability of the surgical experience to perform hernia and minor vascular damage repair surgery is indicated as a surgical necessity. This is also the case in other anterior procedures.

Conclusion

In the treatment of acetabular fractures involving the anterior column the Pararectus approach allowed for anatomic restoration with minimal access morbidity. Results obtained by means of the Pararectus approach at least parallel those obtained using the modified Stoppa approaches after two years. In contrast to the modified Stoppa approach, a relevant extension of the Pararectus approach was almost not necessary. As a result, the Pararectus approach has now become the standard anterior approach in our department and has replaced the modified Stoppa approach for the presented fracture patterns.

Conflict of interests

None.

Source of funding

There was no external funding source.

Acknowledgement

We thank Stephanie Schmutz, study nurse, Department of Orthopaedic and Trauma Surgery, University of Bern, Inselspital for her assistance. We also thank PD Dr D. Bickes-Kelleher for

linguistic help in the preparation of this manuscript. We thank PD Dr E. Aghayev, Institute for Evaluative Research in Medicine, University of Bern for performing the statistical analysis and his assistance in the interpretation of the results.

References

[1] Briffa N, Pearce R, Hill AM, Bircher M. Outcomes of acetabular fracture fixation with ten years' follow-up. J Bone Joint Surg Br Vol 2011;93:229–36.
[2] Ferguson TA, Patel R, Bhandari M, Matta JM. Fractures of the acetabulum in patients aged 60 years and older: an epidemiological and radiological study. J Bone Joint Surg Br Vol 2010;92:250–7.
[3] Tannast M, Najibi S, Matta JM. Two to twenty-year survivorship of the hip in 810 patients with operatively treated acetabular fractures. J Bone Joint Surg Br Vol 2012;94:1559–67.
[4] Anglen JO, Burd TA, Hendricks KJ, Harrison P. The "Gull Sign": a harbinger of failure for internal fixation of geriatric acetabular fractures. J Orthop Trauma 2003;17:625–34.
[5] Mears DC. Surgical treatment of acetabular fractures in elderly patients with osteoporotic bone. J Am Acad Orthop Surgeons 1999;7:128–41.
[6] Rommens PM, Ingelfinger P, Nowak TE, Kuhn S, Hessmann MH. Traumatic damage to the cartilage influences outcome of anatomically reduced acetabular fractures: a medium-term retrospective analysis. Injury 2011;42:1043–8.
[7] Giannoudis PV, Grotz MR, Papakostidis C, Dinopoulos H. Operative treatment of displaced fractures of the acetabulum. A meta-analysis. J Bone Joint Surg Br Vol 2005;87:2–9.
[8] Judet R, Judet J, Letournel E. Fractures of the acetabulum: classification and surgical approaches for open reduction. Preliminary report. J Bone Joint Surg Am Vol 1964;46:1615–46.
[9] Andersen RC, O'Toole RV, Nascone JW, Sciadini MF, Frisch HM, Turen CW. Modified Stoppa approach for acetabular fractures with anterior and posterior column displacement: quantification of radiographic reduction and analysis of interobserver variability. J Orthop Trauma 2010;24:271–8.
[10] Bastian JD, Tannast M, Siebenrock KA, Keel MJ. Mid-term results in relation to age and analysis of predictive factors after fixation of acetabular fractures using the modified Stoppa approach. Injury 2013;44:1793–8.
[11] Cole JD, Bolhofner BR. Acetabular fracture fixation via a modified Stoppa limited intrapelvic approach. Description of operative technique and preliminary treatment results. Clin Orthop Relat Res 1994;305:112–23.
[12] Hirvensalo E, Lindahl J, Kiljunen V. Modified and new approaches for pelvic and acetabular surgery. Injury 2007;38:431–41.
[13] Jakob M, Droeser R, Zobrist R, Messmer P, Regazzoni P. A less invasive anterior intrapelvic approach for the treatment of acetabular fractures and pelvic ring injuries. J Trauma 2006;60:1364–70.
[14] Khoury A, Weill Y, Mosheiff R. The Stoppa approach for acetabular fracture. Operat Orthop Traumatol 2012;24:439–48.
[15] Laflamme GY, Hebert-Davies J, Rouleau D, Benoit B, Leduc S. Internal fixation of osteopenic acetabular fractures involving the quadrilateral plate. Injury 2011;42:1130–4.
[16] Ponsen KJ, Joosse P, Schigt A, Goslings JC, Luitse JS. Internal fracture fixation using the Stoppa approach in pelvic ring and acetabular fractures: technical aspects and operative results. J Trauma 2006;61:662–7.
[17] Sagi HC, Afsari A, Dziadosz D. The anterior intra-pelvic (modified rives-stoppa) approach for fixation of acetabular fractures. J Orthop Trauma 2010;24:263–70.
[18] Stoppa R, Petit J, Abourachid H, Henry X, Duclaye C, Monchaux G, et al. Original procedure of groin hernia repair: interposition without fixation of Dacron tulle prosthesis by subperitoneal median approach. Chirurgie 1973;99:119–23.
[19] Isaacson MJ, Taylor BC, French BG, Poka A. Treatment of acetabulum fractures through the modified Stoppa approach: strategies and outcomes. Clin Orthop Relat Res 2014;472:3345–52.
[20] Shazar N, Eshed I, Ackshota N, Hershkovich O, Khazanov A, Herman A. Comparison of acetabular fracture reduction quality by the ilioinguinal or the anterior intrapelvic (modified rives-stoppa) surgical approaches. J Orthop Trauma 2014;28:313–9.
[21] Ma K, Luan F, Wang X, Ao Y, Liang Y, Fang Y, et al. Randomized, controlled trial of the modified Stoppa versus the ilioinguinal approach for acetabular fractures. Orthopedics 2013;36:e1307–15.
[22] Keel MJ, Ecker TM, Cullmann JL, Bergmann M, Bonel HM, Buchler L, et al. The Pararectus approach for anterior intrapelvic management of acetabular fractures: an anatomical study and clinical evaluation. J Bone Joint Surg Br Vol 2012;94:405–11.
[23] Letournel E. The treatment of acetabular fractures through the ilioinguinal approach. Clin Orthop Relat Res. 1993;292:62–76.
[24] Qureshi AA, Archdeacon MT, Jenkins MA, Infante A, DiPasquale T, Bolhofner BR. Infrapectineal plating for acetabular fractures: a technical adjunct to internal fixation. J Orthop Trauma 2004;18:175–8.
[25] White G, Kanakaris NK, Faour O, Valverde JA, Martin MA, Giannoudis PV. Quadrilateral plate fractures of the acetabulum: an update. Injury 2013; 44:159–67.
[26] Haddad RJ, Cook SD, Brinker MR. A comparison of three varieties of non-cemented porous-coated hip replacement. J Bone Joint Sur Br Vol 1990;72: 2–8.
[27] Harris WH. Traumatic arthritis of the hip after dislocation and acetabular fractures: treatment by mold arthroplasty. An end-result study using a new method of result evaluation. J Bone Joint Surg Am Vol 1969;51: 737–55.
[28] d'Aubigne RM, Postel M. The classic: functional results of hip arthroplasty with acrylic prosthesis. 1954. Clin Orthop Relat Res 2009;467:7–27.
[29] Matta JM. Operative treatment of acetabular fractures through the ilioinguinal approach. A 10-year perspective. Clin Orthop Relat Res 1994;305:10–9.
[30] Matta JM. Fractures of the acetabulum: accuracy of reduction and clinical results in patients managed operatively within three weeks after the injury. J Bone Joint Sur Am Vol 1996;78:1632–45.
[31] Bellamy N, Buchanan WW, Goldsmith CH, Campbell J, Stitt LW. Validation study of WOMAC: a health status instrument for measuring clinically important patient relevant outcomes to antirheumatic drug therapy in patients with osteoarthritis of the hip or knee. J Rheumatol 1988;15:1833–40.
[32] Ware Jr J, Kosinski M, Keller SD. A 12-Item Short-Form Health Survey: construction of scales and preliminary tests of reliability and validity. Med Care 1996;34:220–33.
[33] Zahiri CA, Schmalzried TP, Szuszczewicz ES, Amstutz HC. Assessing activity in joint replacement patients. J Arthroplasty 1998;13:890–5.
[34] Tonnis D, Heinecke A. Acetabular and femoral anteversion: relationship with osteoarthritis of the hip. J Bone Joint Surg Am Vol 1999;81:1747–70.
[35] Brooker AF, Bowerman JW, Robinson RA, Riley Jr LH. Ectopic ossification following total hip replacement. Incidence and a method of classification. J Bone Joint Surg Am Vol 1973;55:1629–32.
[36] Ficat P, Arlet J. [Pre-radiologic stage of femur head osteonecrosis: diagnostic and therapeutic possibilities]. Revue de Chirurgie Orthopédique et Réparatrice de l'Appareil Moteur 1973;59. Suppl 38.
[37] Sermon A, Broos P, Vanderschot P. Total hip replacement for acetabular fractures. Results in 121 patients operated between 1983 and 2003. Injury 2008;39:914–21.
[38] Tannast M, Kruger A, Mack PW, Powell JN, Hosalkar HS, Siebenrock KA. Surgical dislocation of the hip for the fixation of acetabular fractures. J Bone Joint Surg British Vol 2010;92:842–52.